



Case Report

Transient osteoporosis: Not just the hip to worry about

Nicola Berman, MD^{a,*}, Howard Brent^b, Gregory Chang^c, Stephen Honig^d^a Department of Rheumatology, Hospital for Joint Diseases, United States^b American University of the Caribbean, 901 Ponce de Leon Boulevard, Suite 700, Coral Gables, FL 33134, United States^c NYU Department of Radiology, 660 1st Avenue, New York, NY 10003, United States^d Department of Rheumatology, The Osteoporosis Center at NYU Hospital for Joint Disease, 301 East 17th Street, New York, NY 10003, United States

ARTICLE INFO

Article history:

Received 7 September 2016

Received in revised form 26 September 2016

Accepted 14 October 2016

Available online 15 October 2016

Keywords:

Transient osteoporosis

Transient osteoporosis of the hip

Transient osteoporosis of the knee

Bone marrow edema

High resolution 7 T MRI

ABSTRACT

Transient osteoporosis (TO) is a clinical syndrome characterized by joint pain and the presence of bone marrow edema on magnetic resonance imaging (MRI), both of which spontaneously resolve over time. Transient osteoporosis most commonly affects the hip, but also may involve other lower extremity sites. TO likely represents a disorder that may be monoarticular or “migratory” with involvement of two or more lower extremity sites sequentially affected over a number of months. We report on two cases of transient osteoporosis, one involving the knee and one involving the hip, demonstrating the utility of serial bone mineral density measurements at both sites. Additionally, we are able to report on the microarchitectural changes seen at the distal femur on ultra-high resolution (7 T) MRI. Case #1 describes a recurrence of transient osteoporosis of the hip three years after a similar presentation at the contralateral hip and highlights the findings of rapidly changing bone mineral density in this clinical syndrome. In contrast to the spine, hip and forearm, peripheral bone density measurements at the knee are rarely reported and to our knowledge Case #2 represents the first report of transient osteoporosis of the knee demonstrating bone density findings similar to that seen in the hip. We postulate that transient osteoporosis of the knee is part of a clinical spectrum most commonly seen in the hip and one that is marked by lower extremity joint pain, bone marrow edema on MRI and transient decreases in bone mineral density all of which spontaneously resolve without sequelae.

Published by Elsevier Inc. This is an open access article under the CC BY-NC-ND license (<http://creativecommons.org/licenses/by-nc-nd/4.0/>).

1. Introduction¹

Transient osteoporosis (TO) is characterized by self-limited joint pain and by the presence of bone marrow edema on magnetic resonance imaging (MRI). TO most commonly affects the hip², but has also been reported to involve the knee, ankle and foot (Zabalbeascoa et al., 1999). The presence of bone marrow edema (BME)³ on MRI is non-specific and is commonly reported in many conditions that affect the knee (Suresh et al., 2009). We hypothesize that in many cases, BME on MRI actually represents unrecognized TO, and that TO of the knee is more common than previously reported, since a lack of clinical awareness of TO by many health care providers may lead them to misdiagnose subjects with severe, atraumatic knee pain. We propose that TO of the knee is a manifestation of the same process that occurs in the hip.

Moreover, we postulate that the migratory nature of this syndrome as seen in some patients is a reflection of a disorder that may involve one or more joints with the hip being the most common site. In the absence of osteonecrosis, osteoarthritis or meniscal tears, TO of the knee should be strongly considered in the presence of BME, especially when the clinical manifestations subsequently resolve spontaneously. We present two cases of TO, one at the hip and one at the knee, to highlight the transient and self-resolving nature of this disorder and to demonstrate how advances in imaging and targeted bone mineral density tests can distinguish TO from other causes of BME.

2. Case #1

A 35-year-old male presented to the NYU-Hospital for Joint Disease Osteoporosis Center with progressive pain in his left hip, limiting his ability to ambulate. He denied any antecedent event or trauma preceding the onset of pain. Initial X-rays showed marked demineralization of the left femoral head and neck. A subsequent MRI revealed diffuse bone marrow edema of the left femoral head and neck with a suggestion of a possible subchondral fracture and a moderate hip joint effusion. Bone densitometry of the left femoral neck revealed a BMD of 0.783 g/cm²

* Corresponding author.

E-mail addresses: Nicola.berman@nyumc.org (N. Berman),Howardbrent@students.aucmed.edu (H. Brent), Gregory.chang@nyumc.org (G. Chang),Stephen.honig@nyumc.org (S. Honig).¹ Transient Osteoporosis (TO).² Transient Osteoporosis of the Hip (TOH).³ Bone Marrow Edema.

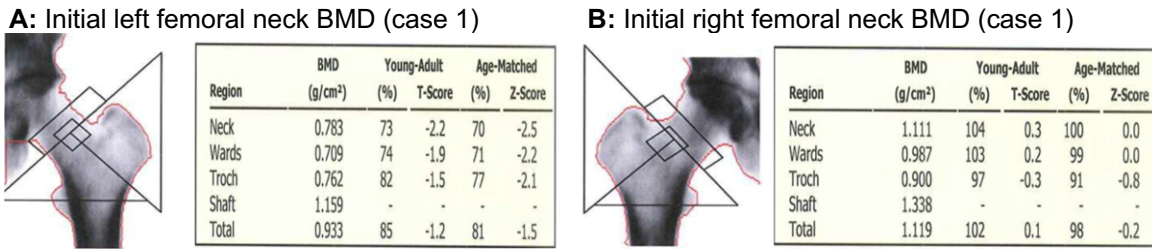


Fig. 1. A: Left femoral neck BMD of 0.783 g/cm² and a T-score of -2.1; B: Normal right femoral neck bone density of 1.111 and a T score of +0.

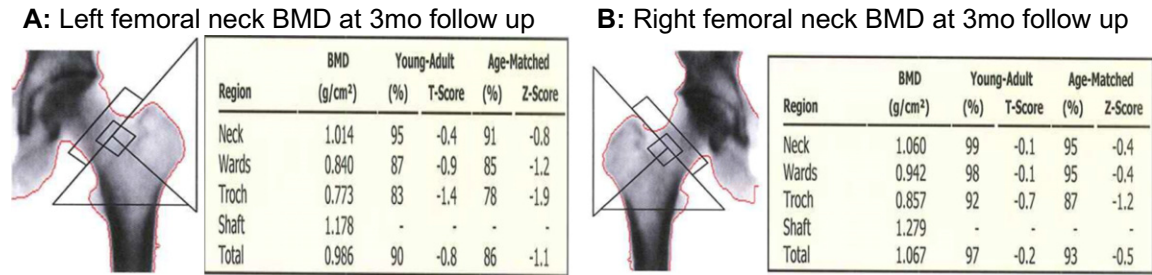


Fig. 2. A and B: Repeat BMD testing at 3 months revealing normal left and right femoral neck bone density.

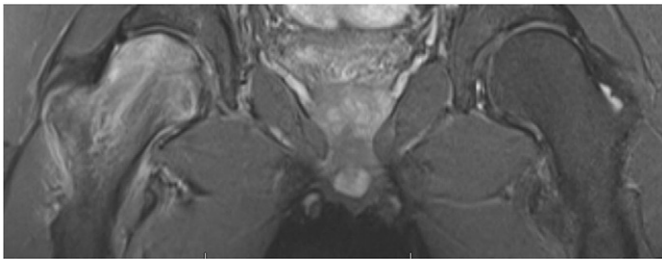


Fig. 3. MRI of right hip revealing diffuse bone marrow edema.

and a Z-score of -2.5, compared with a normal right femoral neck bone density of 1.111 with a Z score of +0.0 (Fig. 1 A and B). A diagnosis of TO was made and the patient was empirically started on risedronate 35 mg once weekly, which he used weekly for twelve weeks. Additionally, he was started on calcium and vitamin D supplementation. Repeat radiographs after three months showed complete remineralization of the femoral head and neck. A repeat bone mineral density test now showed a normal left femoral neck bone mineral density of 1.014 g/cm² and a Z score of -0.8. His right femoral neck bone density remained normal (Fig. 2 A and B). At that time, the patient reported complete resolution of his symptoms and was able to proceed with pain-free weight bearing.

Three years later, the patient developed a peroneus tendinitis of his right foot that required him to wear a cam walker. Within one month, he developed severe pain in his right hip and he was unable to bear weight on his right foot. Radiographs of the right hip were

unremarkable. An MRI revealed diffuse bone marrow edema (Fig. 3) and a minimally depressed subchondral fracture at the anterosuperior femoral head, similar to the changes seen in the left hip three years prior. A bone density test revealed a right femoral neck BMD of 0.836 g/cm² with a Z score of -2.0. His left femoral bone density was normal (Fig. 4 A and B). He was again empirically treated with a three month course of risedronate. His pain resolved completely two months after onset.

2.1. Case #2

A 64-year-old, previously healthy male presented to his orthopedic surgeon with a two-week history of progressively increasing left knee pain. He localized the pain to the lateral aspect of the distal femur and complained that the pain increased after sitting for prolonged periods and with stair climbing. He denied any trauma to the knee but had recently increased his exercise regimen and reported that he had been running on a treadmill more frequently than he had previously done. A radiograph of the knee was unremarkable. An MRI of the left knee revealed marked bone marrow edema as well as a focal subchondral fracture in the weight-bearing region of the lateral femoral condyle (Fig. 5). In addition, a high-resolution 7 T MRI of his left distal femur revealed deterioration in bone microarchitecture (manifested by trabecular loss and disruption), as compared to the right. (Fig. 6). A regional knee bone mineral density test showed his left lateral femoral condyle BMD to be 0.96 g/cm². Additional routine evaluation including ensuring adequate levels of 25-dihydroxyvitamin D, did not yield any abnormalities or areas for possible intervention. The patient did continued with

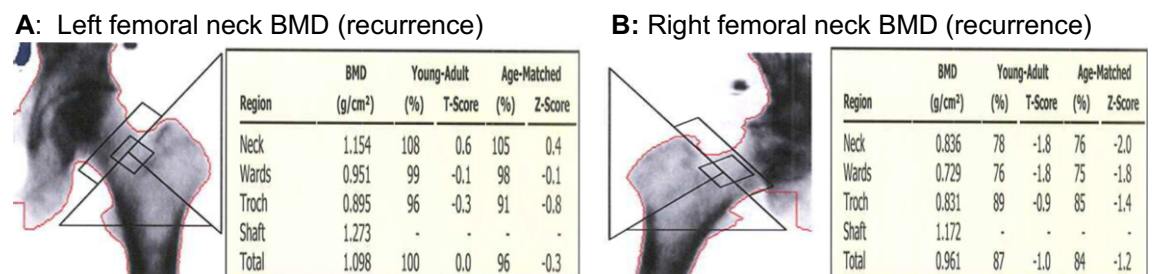


Fig. 4. Repeat BMD when patient presented with right hip pain. A: Normal left femoral neck BMD. B: Right femoral neck BMD of 0.836 g/cm² with a T score of -1.8.

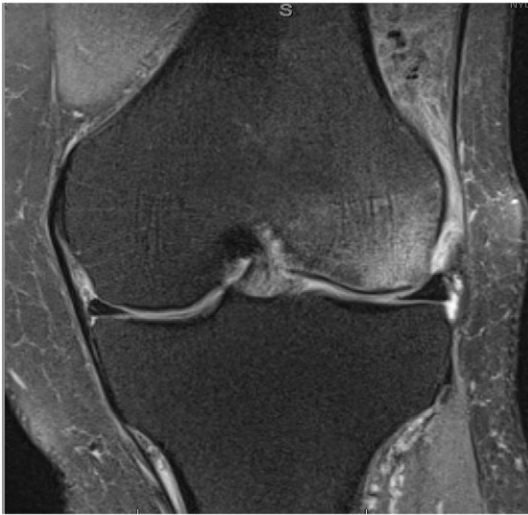

Fig. 5. MRI of the left knee revealing marked bone marrow edema and focal subchondral fracture in the weight-bearing region of the lateral femoral condyle.

routine calcium and vitamin D supplementation. The patient reported spontaneous resolution of his knee pain over the next month. A repeat regional knee bone density of the left lateral femoral condyle showed marked improvement with a BMD of 1.63 g/cm² at one year follow up (Fig. 7 A and B).

3. Discussion

TO of bone is an uncommon, self-limited clinical syndrome, characterized by the acute onset of joint pain and the presence of bone marrow edema on MR imaging (Suresh et al., 2009; Hayes et al., 1993). TO mainly affects healthy middle-aged men, and women in the third trimester of pregnancy. The bones/joints of the lower extremities are most commonly affected with the hip most frequently involved followed in order of frequency by the knee, foot and ankle (Zabalbeascoa et al., 1999; Lakhnopal et al., 1987). Although it is most often unilateral a bilateral incidence of 20% (as seen in Case #1) has been reported in a Japanese study (Suresh et al., 2009; Klontzas et al., 2015).

Although the cause of TO is unknown, multiple etiopathogenic mechanisms have been proposed (Diwanji et al., 2008). The presence of a joint effusion in nearly all cases of TO suggests synovial

involvement, but investigation has revealed only non-specific synovial fluid findings. A limited number of synovial biopsies performed in patients with TO have shown only mild inflammatory reactions (McCord et al., 1978). Based on common EMG findings it has also been suggested that TO is a variant of reflex sympathetic dystrophy (Hayes et al., 1993). Yet a third hypothesis is that the TO effect on bone occurs secondary to a transient ischemic insult, suggesting that TO and osteonecrosis may exist on a spectrum ranging from transient and reversible bone injury to extensive bone death. However, in one study of 155 patients diagnosed with TO of the hip by imaging criteria, none of the patients progressed to osteonecrosis, casting doubt on the suggestion that TOH is part of a clinical spectrum that may result in either spontaneous resolution (TOH) or avascular bone death (Lakhnopal et al., 1987; Klontzas et al., 2015). Moreover, none of the proposed pathogenic theories explain why there is an increased incidence of TO in men or pregnant women (Diwanji et al., 2008).

TOH most commonly presents with spontaneous and severe unilateral hip pain. The pain often progresses over several weeks. Patients characteristically deny any antecedent history of trauma. The pain is typically exacerbated by activity and weight bearing (McWalter and Hassan, 2009). Bone loss, as seen in our Case #1, occurs most prominently in the femoral neck and head. Klontzas et al. retrospectively evaluated 155 hip joints in patients with confirmed TOH initially diagnosed by MR imaging. In this study, 87% of the MRIs showed sparing of the medial bone marrow of the femoral head. Only 11% of the MRIs showed BME restricted to femoral head. The femoral neck was involved in 49% of cases. Subchondral fractures were present in 48%, though, of note, no statistically significant association between the duration of symptoms and the presence of subchondral fractures was reported (Klontzas et al., 2015). In TO of the hip, the clinical trajectory can vary, but symptoms usually plateau after a few weeks and then gradually decline over the following 3–9 months until there is complete resolution of symptoms (Diwanji et al., 2008).

TO of the knee, though rarely reported in literature, has been described in the context of a bone marrow edema syndrome. A number of cases have reported this entity, with the classic resolution of bone marrow edema without intervention at twelve-month follow up. The femoral condyles have been the most common sites reported to be involved in this syndrome (Nikolaou et al., 2008; Parker et al., 1997). MRI may reveal a classic “crescent” region of increased signal intensity in the posterior portion of the lateral femoral condyle. This is a faint rim of low signal intensity on T1 weighted imaging and a more well-defined area of low signal intensity on T2 weighted images which has been thought to resemble the “fluid-like” changes described in osteonecrosis

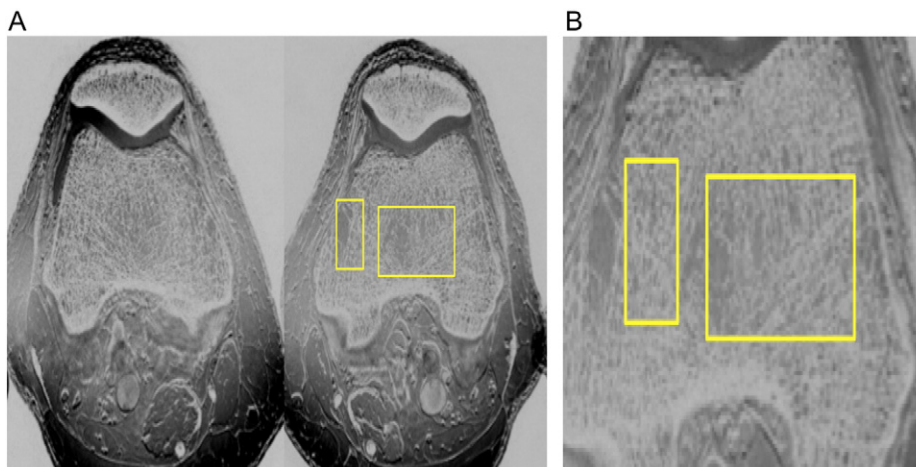


Fig. 6. A: High resolution 7 T MRI revealing deterioration of bone microarchitecture in the affected left knee (boxes) compared to the unaffected right knee; B: Higher power view of microarchitectural changes affecting distal femur.

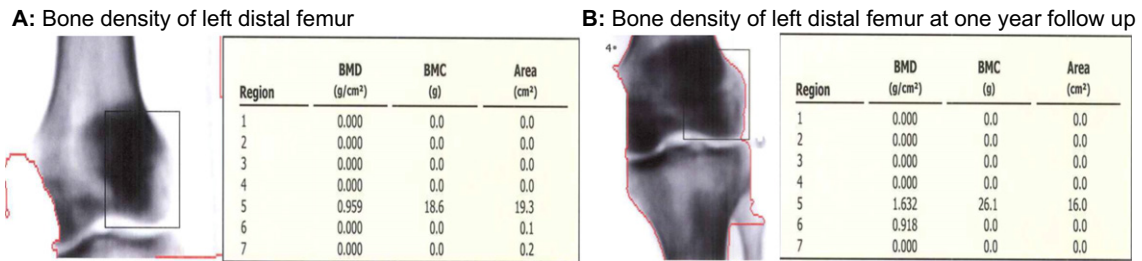


Fig. 7. A and B: Bone density of left distal femur showing regional osteopenia with marked improvement of BMD at one year follow up.

by Mitchell et al. TO of the knee has also been diagnosed by radioisotope bone scans that demonstrate increased radionuclide uptake in these focal regions (Lakhanpal et al., 1987; Mitchell et al., 1987).

There are no biomarkers or other laboratory tests that are helpful in making a diagnosis of TO although some patients may have elevated acute phase reactants (Lakhanpal et al., 1987). The hallmark sign of TO on MRI is bone marrow edema. The T1 weighted images will show an ill-defined area of decreased signal intensity, with increased signal intensity on the T2 weighted images; T2 weighted imaging may also reveal a joint effusion. Bone marrow edema can be classified into two categories: reversible with conservative treatment such as TO, Regional Migratory Osteoporosis, chronic regional pain syndrome, trauma, and non-reversible such as avascular necrosis, infection, tumors and degenerative and inflammatory arthropathies (Diwanji et al., 2008; Klontzas et al., 2015). These syndromes have all been reported to produce a similar pattern of bone marrow edema (BME) on MR. TO can be distinguished from other causes of bone marrow edema, particularly osteonecrosis, by its self-limited nature (Hayes et al., 1993).

In our patient (Case #2) who developed TO of the knee, we used bone densitometry of the distal femur to help confirm the diagnosis. To our knowledge, this is the first reported case using peripheral bone densitometry to confirm a diagnosis of the distal femur in TO. Our group has previously reported the utility of bone densitometry of the femoral neck by demonstrating marked bone loss and subsequent resolution back to a normal bone density with complete clinical remission (Cadet and Honig, 2009). Case #2 extends the use of this modality to regional bone sites and is now a routine part of our evaluation of patients with bone marrow edema who are referred to our facility. We have not seen localized bone loss in other patients with bone marrow edema of the knee including those with osteoarthritis, osteonecrosis and meniscal tears. The serial measurements seen in the bone density scans in both our cases correlated both with their clinical courses and the initial and follow up MRI scans showing resolution of the BMD. Of note, the study mentioned above (Klontzas et al.) did measure bone densitometry on 30 of their patients, of which 31 showed osteopenia and 30 showed osteoporosis, however these measurements were taken from the lumbar spine and not the site of pain and local bone loss (Klontzas et al., 2015). Additionally, we utilized a high-resolution 7 T MRI machine in Case #2 which allowed us to clearly see the trabecular microarchitectural deterioration of his affected knee compared to his contralateral and uninvolved knee. This finding is, to our knowledge, the first reported use of this technology for this application.

Bone marrow edema is a common finding on MRI and is often seen in patients with knee pain with a variety of clinical conditions. We believe that transient osteoporosis of the knee is likely the cause of knee pain in some of these patients particularly those who experience spontaneous resolution both of their knee pain and the BME seen on MRI. Regional bone density measurements confirm that localized bone loss occurs in both the hip and knee of patients with TO and that this bone loss is

indeed transient in nature. Bone marrow edema of the knee appears to be found as a result of a number of conditions including meniscal tears, osteoarthritis, trauma and regional osteoporotic syndromes. Patients with bone marrow edema in association with transient osteoporosis often have severe pain, but the pain levels seen with these other conditions is quite variable (Hayes et al., 1993).

Whether treatment with anti-resorptive agents affects the natural course of TO is unknown. Treatment with such agents including calcitonin and bisphosphonates has been reported to alleviate pain and accelerate both clinical and radiologic recovery. However, most of this data comes from case reports and uncontrolled case series (Bolland, 2008). The rarity of this syndrome makes it unlikely that a randomized controlled trial assessing the therapeutic efficacy of any drug for TO will be conducted. Empiric treatment with anti-resorptive agent can be offered to patients with TO, as was done in Case #1, but patients should know that there is no firm data suggesting that such treatment is effective. In the two patient's described, there were no quantified bone scans or bone markers to suggest increased turnover. These values have been checked in this specific population the past by our group and were not elevated.

References

Bolland, M.J., 2008. Bilateral transient osteoporosis of the hip in a young man. *J. Clin. Densitom.* 11 (2), 339–341 (Apr).

Cadet, M., Honig, S., 2009. Utility of bone densitometry in diagnostic evaluation and monitoring in regional migratory osteoporosis. *J. Clin. Rheumatol.* 15 (3), 124–126 (Apr).

Diwanji, S.R., Cho, Y.J., Xin, Z.F., Yoon, T.R., 2008. Conservative treatment for transient osteoporosis of the hip in middle-aged women. *Singap. Med. J.* 49 (1), 17–21.

Hayes, C.w., Conway MD, M.D.W.F., Daniel MD, P.D.W.W., 1993. The MRI imaging of bone marrow edema pattern: transient osteoporosis, transient bone marrow edema syndrome, or osteonecrosis. *Radiographis* 13 (5), 1001–1011.

Klontzas, M.E., Vassalou, E.E., Zibis, A.H., Bintoudi, A.S., Karantanas, A.H., 2015. MR imaging of transient osteoporosis of the hip: an update on 155 hip joints. *Eur. J. Radiol.* 84 (3), 431–436 (Mar).

Lakhanpal, S., Ginsburg, W.W., Luthra, H.S., Hunder, G.G., 1987. Transient regional osteoporosis. A study of 56 cases and review of the literature. *Ann. Intern. Med.* 106 (3), 444–450 (Mar).

McCord, W.C., Nies, K.M., Capion, D.S., Louie, J.S., 1978. Regional migratory osteoporosis: an enervation disease. *Arthritis Rheum.* 21, 834–838.

McWalter, P., Hassan, A., 2009. Transient osteoporosis of the hip. *Ann. Saudi Med.* 29 (2), 146 (Mar–Apr).

Mitchell, D.G., Rao, V.M., Dalinka, M.K., Spritzer, C.E., Alavi, A., Steinberg, M.E., Fallon, M., Kressel, H.Y., 1987. Femoral head avascular necrosis: correlation of MR imaging, radiographic staging, radionuclide imaging, and clinical findings. *Radiology* 162, 709–715.

Nikolaou, V.S., Pilichou, A., Korres, D., Efstathopoulos, N., 2008. Transient osteoporosis of the knee. *Orthopedics* 31 (5), 502 (May).

Parker, R.K., Ross, G.J., Urso, J.A., 1997. Transient osteoporosis of the knee. *Skelet. Radiol.* 26 (5), 306–309 (May).

Suresh, S., Thomas, J.K., Raniga, S., 2009. Migrating transient osteoporosis of the hip in a 30 year old man. *Indian J. Orthop.* 43 (3), 301–304 (Jul).

Zabalbeascoa, R., Rodas, A., Sousa, M., Carrascusa, P., Caparros, M., 1999. Transient osteoporosis of the hip. *Int. Orthop.* 23, 244–246.